

Residents' Corner

Cause of pancytopenia in a young female: Think differently

Chirasree Sanyal

Department of Hematology, NRS Medical College, Kolkata, West Bengal, India.

***Corresponding author:**

Chirasree Sanyal,
Department of Hematology,
NRS Medical College, Kolkata,
West Bengal, India.

drchirasreesanyal@gmail.com

Received : 19 October 2022

Accepted : 20 October 2022

Published : 29 October 2022

DOI

10.25259/JHAS_30_2022

Quick Response Code:



A 15-year-old female presented with fever, bilateral periorbital swelling, oral ulcer, and skin rash [Figure 1a and b – before starting therapy]. Complete blood count revealed pancytopenia; no abnormal cells found. The patient required transfusions with several units of packed RBC and platelet concentrates due to symptomatic pallor and mucosal bleeding manifestations from multiple sites. Blood biochemistry and baseline coagulation parameter were within normal range, serum Vitamin B12 and folate were normal; other inflammatory markers were negative. Magnetic resonance imaging of brain with orbit revealed no abnormalities. Bone marrow study revealed reactive marrow with no significant changes. Anti-nuclear antibody (ANA) profile revealed strong ANA positivity (by Hep-2 cell line) and anti-dsDNA negative and strong positivity for anti-nucleosome antibody. Rheumatologist opinion taken: Diagnosed as a case of systemic lupus erythematosus (SLE) as per European League against Rheumatism/American College of Rheumatology criteria 2019. The patient was started with oral prednisolone (0.5 mg/Kg of body weight) and hydroxychloroquine sulfate (HCQS, 200 mg every 12 hourly) was started. Cytopenia recovered dramatically and completely after 5 days of starting therapy. The periorbital swelling reduced dramatically and skin rash also diminishing gradually

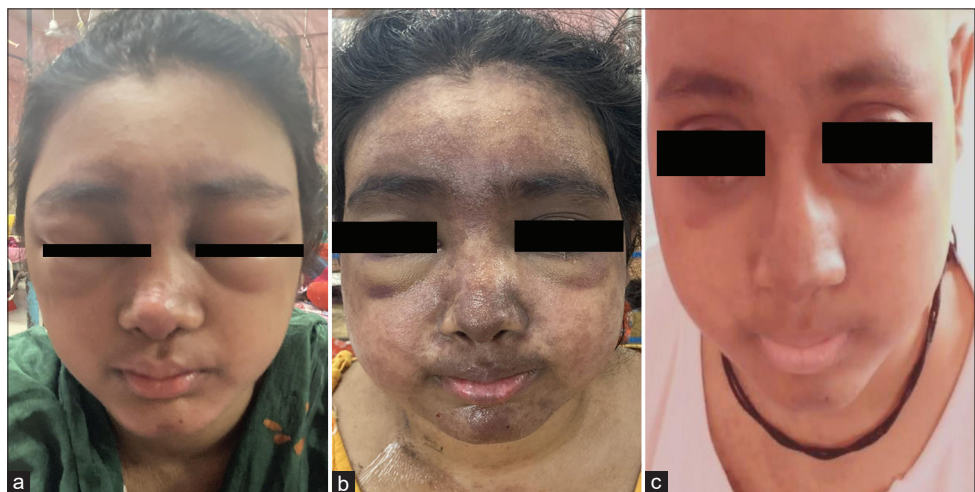


Figure 1: (a) Bilateral periorbital swelling, (b) skin rash, and (c) patient 2 weeks after starting therapy.

This is an open-access article distributed under the terms of the Creative Commons Attribution-Non Commercial-Share Alike 4.0 License, which allows others to remix, transform, and build upon the work non-commercially, as long as the author is credited and the new creations are licensed under the identical terms.

©2022 Published by Scientific Scholar on behalf of Journal of Hematology and Allied Sciences

[Figure 1c – 2 weeks after starting therapy]. At present, the patient is transfusion independent, doing well and under regular follow-up. While evaluating a case of pancytopenia in a young female, SLE should be suspected for and investigated properly, not to miss this not so uncommon clinical entity.

Declaration of patient consent

The authors certify that they have obtained all appropriate patient consent.

Financial support and sponsorship

Nil.

Conflicts of interest

There are no conflicts of interest.

How to cite this article: Sanyal C. Cause of pancytopenia in a young female: Think differently. J Hematol Allied Sci 2022;2:101-2.