

Original Research

Comparison of bone marrow aspiration and biopsy as diagnostic tool in pediatric age group

Rhituparna Das¹, Ankita Pranab Mandal¹, Moupali Ghosh², Moumita Sengupta³

¹Department of Pathology, Institute of Post Graduate Medical Education and Research, Kolkata, ²Department of Clinical Haematology, Institute of Haematology and Transfusion Medicine, Kolkata, ³Department of Oncopathology, Dr B Borooah Cancer Institute, A unit of Tata Memorial Hospital Mumbai, Guwahati, Assam, India.

***Corresponding author:**

Dr. Moumita Sengupta,
Protech Tarahira, Birubari,
Guwahati, Assam, India.

moumitasengupta83@gmail.com

Received: 23 January 2023
Accepted: 06 March 2023
Epub Ahead of Print: 20 June 2023
Published: 11 July 2023

DOI
10.25259/JHAS_2_2023

Quick Response Code:



ABSTRACT

Objectives: Bone marrow examination is the final endpoint to the diagnosis of many haematological and non-haematological disorders when all other clinical diagnostic tools have been done with. It consists of two tests each of which has their own role in making a final diagnosis. First bone marrow aspiration and second bone marrow biopsy. They complement each other and together provides a complete picture of the bone marrow. The study aimed to assess the diagnostic accuracy and to observe the degree of correlation (kappa value) between the two procedures.

Material and Methods: This retrospective study was conducted in the department of pathology of our institution from July 2021 to August 2022. In 149 cases, both BMA and BMB was performed simultaneously and was included in the study. BMA slides was stained with Leishman Giemsa stain and BMB underwent tissue decalcification and tissue processing followed by staining with haematoxylin and eosin stain. Other special stains such as PAS, Reticulin and Perl's, ZielNeelson (ZN) stain were also done on all relevant cases. Data were analyzed using Graphpad Instat 3 and Prism 5.

Results: The mean age was 8.23±4.37. Of these, the Male: Female ratio was 1.8:1. The most commonly correlated diagnosis in the lower age group were for iron deficiency anemia (100%), Childhood Acute Leukemia (87.2%) and in higher age groups, the most correlated diagnosis were for Chronic myeloid Leukaemia (100%) and Acute Myeloid Leukaemia (72.72%). Kappa value in our study revealed that there was substantial agreement (0.6295) between the two procedures. the diagnostic efficacy of BMA is 77.18% and for BMB is 90.6%.

Conclusion: Bone marrow aspiration and biopsy have upperhand over each other in their respective area. Both shows substantial agreement and hence these should be performed together and not in isolation to give a complete diagnosis.

Keywords: Bone marrow aspiration, Biopsy, Pediatric age group

INTRODUCTION

Bone marrow examination (BME) is the final endpoint to the diagnosis of many hematological and non-hematological disorders when all other clinical diagnostic tools have been done with. Many times marrow unravels the etiological agent behind pyrexia of unknown origin or pancytopenia diagnosed clinically. They are also meant to assess response to chemotherapy and staging of lymphomas. Rare instances of occult malignancies or storage disorders only came out of a marrow examination.^[1,2] Marrow reveals the true picture of underlying hematopoiesis which peripheral blood fails to provide. It consists of two tests each of which has its own role in

This is an open-access article distributed under the terms of the Creative Commons Attribution-Non Commercial-Share Alike 4.0 License, which allows others to remix, transform, and build upon the work non-commercially, as long as the author is credited and the new creations are licensed under the identical terms.

©2023 Published by Scientific Scholar on behalf of Journal of Hematology and Allied Sciences

making a final diagnosis. First bone marrow aspiration and second bone marrow biopsy. They complement each other and together provide a complete picture of the bone marrow. This study aims to assess the diagnostic accuracy and to observe the degree of correlation (kappa value) between the two procedures.

MATERIAL AND METHODS

This retrospective study was conducted in the department of pathology of our institution from July 2021 to August 2022 wherein a total number of 257 bone marrow aspirates (BMA) and 192 bone marrow biopsies (BMB) were reviewed. This study was approved by the research ethics committee. In 149 cases, both BMA and BMB were performed simultaneously. Children and adolescents were included in this study. Patients who did not undergo bone marrow biopsy due to a deranged coagulation profile were excluded from the study.

The site for BMA and BMB was the posterior superior iliac spine. Jamshidi bone marrow biopsy/aspiration needle with Luer lock adapter was used, 13 gauge needle for lower age group and 11 gauge needle for higher age groups. BMA slides were stained with Leishman Giemsa stain. The BMB was fixed in 10% neutral buffered formalin for overnight. Biopsies underwent tissue decalcification and tissue processing followed by staining with hematoxylin and eosin stain. Other special stains such as Periodic Acid Schiff (PAS), Reticulin and Perl’s, Ziehl neelsen stain were also done on all relevant cases. Data were analyzed using GraphPad InStat 3 and Prism 5.

RESULTS

During the study period of 1 year 149 BMEs, both bone marrow aspirations and BMB were performed for various indications. The mean age was 8.23 ± 4.37 . Of these, the Male: Female ratio was 1.8:1 [Table 1 and Figure 1]. Fever was the most common presentation along with gum bleeding, hepatomegaly, and splenomegaly [Figure 2]. This was followed by anemia which was followed by the need for recurrent transfusion. Leukemia, iron deficiency anemia (IDA), and storage disorders like Gaucher’s dominated the lower strata of the study age group, while hemolytic anemia,

Table 1: Age and sex distribution of the cases (n=149).

Age	Male	Female
<2	3	4
2-5	22	15
>5-15	64	29
>15	7	5
Total	96	53

macrophage activation syndrome hypersplenism, dominated the higher age groups [Figure 3].

The diagnostic findings of BMA, biopsy, and percentage of correlation, respectively, for different diseases, are summarized in [Table 2]. The most correlated diagnosis in the lower age group was for IDA (100%), childhood acute leukemia (87.2%), megaloblastic anemia (MA) (83.3%), and erythroid hyperplasia (EH) (80%). In higher age groups, the most correlated diagnosis was for chronic myeloid leukemia (100%) and acute myeloid leukemia (72.72%) [Figures 4-6]. Out of the 149 cases, aspirate was diagnostic in 115 cases (77.18%) while the biopsy was diagnostic in 135 cases (90.60%). The majority (77.18%) of the cases showed a significant correlation between the BMA and biopsy findings.

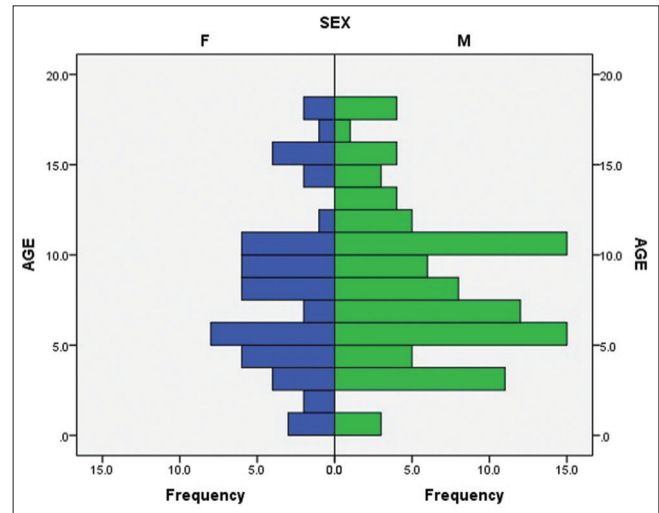


Figure 1: Graphical representation of age and sex distribution of the cases (n = 149).

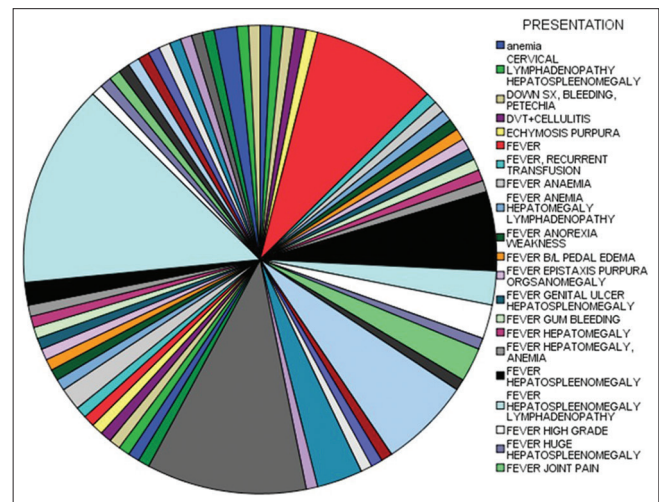


Figure 2: Graphical representation of the frequency of the symptoms among the cases (n = 149).

We also calculated the Kappa value in the table to find out the degree of correlation between these two procedures [Table 3]. Kappa value in our study revealed that there was substantial agreement (0.6295) between the two procedures, thereby, implying that any single one can be used for diagnosis if the other is not available or possible due to the scanty amount of tissue received. In this study, the diagnostic efficacy of BMA is 77.18%, and for BMB is 90.6%.

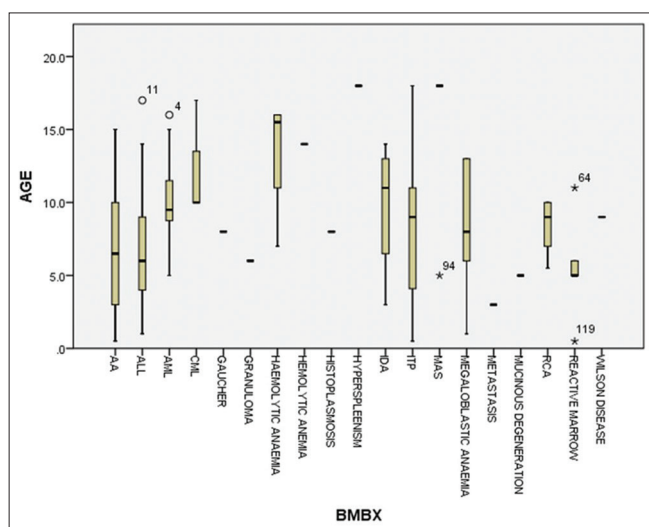


Figure 3: Graphical representation of the frequency of the cases among the different age groups (n = 149).

DISCUSSION

Bone marrow studies are becoming an indispensable tool in diagnosis in the present age. Although both procedures complement each other, yet there is an emerging need for the identification of an accurate one for early diagnosis and the start of treatment. Furthermore, since both procedures have their pros and cons, this study is an attempt to identify those conditions in which each of these has its part to play. The mean age was 8.23 ± 4.37 . Of these, the Male: Female ratio was 1.8:1 which was concordant with the other studies.^[1,3,4] The results of the study were grouped into diagnosis was possible by bone marrow aspiration alone, diagnosis possible with combined aspiration and biopsy, no diagnostic clue on aspiration but biopsy proven diagnosis and non-diagnostic.

Of the total aspirate smears, some cases were unclassified. The reasons for these are diverse. First, hypocellular marrow which was followed up till biopsy showed that there was a marked increase in reticulin fibers suggesting myelofibrosis and resulting pancytopenia with a dry tap. These were the cases with acute myeloblastic leukemia (AML). All cases were picked up by trephine biopsy which was missed on aspiration. Next, there were instances when a biopsy revealed complete replacement of hematopoietic cells by blasts. Here, trephine biopsy was of utmost importance in diagnosis. These were cases of acute lymphoblastic leukemia. About 12% of cases in our study were missed on aspiration due to low cellularity or

Table 2: Diagnostic findings of bone marrow aspirate, biopsy, and percentage of correlation (n=149).

Diagnosis	Complete correlation (%)	Partial correlation	No correlation	Unclassified	Total
ALL	41 (87.23)	3	1	2	47
AML	8 (72.72)	2	0	1	11
AA	15 (68.18)	0	2	5	22
CML	3 (100)	0	0	0	3
EH	4 (80)	0	1	0	5
MA	5 (83.33)	1	0	0	6
IDA	9 (100)	0	0	0	9
MAS	3 (60)	0	1	1	5
RCA	6 (85.71)	0	0	1	7
SD	1 (33.33)	0	1	1	3
GR	0	0	1	0	1
HS	0	0	1	0	1
HIS	1 (100)	0	0	0	1
MET	0	0	1	0	1
MUD	0	0	0	1	1
ITP	13 (68.42)	0	5	1	19
WD	1 (100)	0	0	0	1
RM	5 (83.33)	0	0	1	6
UN	0	0	0	0	0
Total	115 (77.18)	6	14	14	149

AML: Acute myeloblastic leukaemia, AA: Aplastic anaemia, CML: Chronic myeloid leukaemia, EH: Erythroid hyperplasia, MA: Megaloblastic anemia, IDA: Iron deficiency anaemia, MAS: Macrophage activation syndrome, RCA: Red cell aplasia, ITP: Immune thrombocytopenic purpura, SD: Storage disorders, GR: Granulomatous inflammation, HS: Hereditary spherocytosis, HIS: Histoplasma capsulatum infection, MET: Metastasis, MUD: Mucinous degeneration, WD: Wilson disease, RM: Reactive marrow, UN: Unclassified

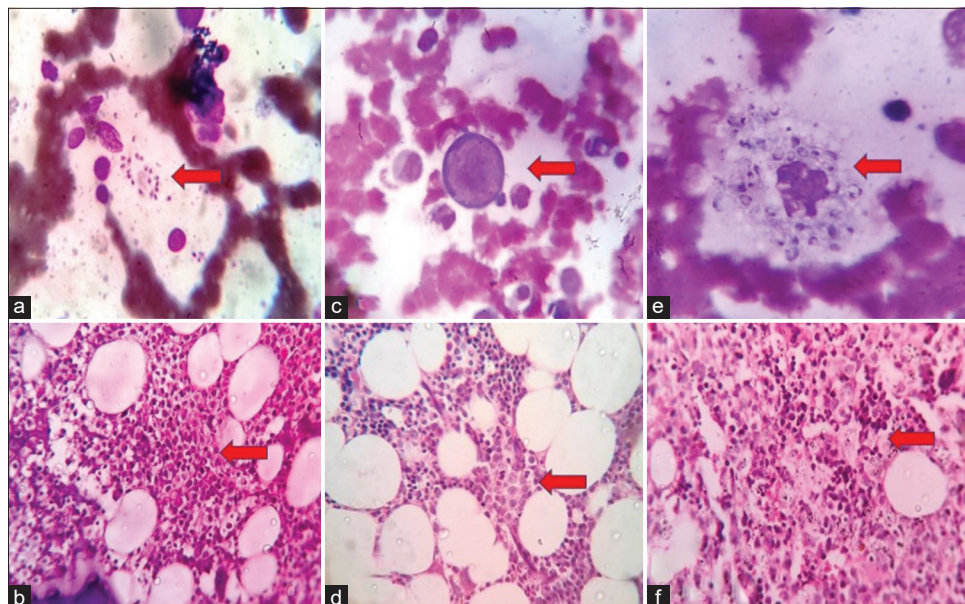


Figure 4: *Leishmania donovani* (L.D.) bodies (a) Bone marrow aspiration smear shows a macrophage loaded with L.D. bodies and some L.D. bodies are present extracellular (LG, ×400) (b) Bone marrow trephine biopsy shows numerous macrophages loaded with L.D. bodies (H and E, ×400) Parvovirus B19 infection (c) Bone marrow aspiration smear shows giant proerythroblasts having large size, sieve like nuclear chromatin with intranuclear inclusion with cytoplasmic protrusions (LG, ×400) (d) Bone marrow trephine biopsy shows giant proerythroblasts with vesicular round oval nuclei and intranuclear inclusion (H and E, ×400) *Histoplasma capsulatum* infection (e) Bone marrow aspiration smear shows a macrophage loaded with yeast forms with a distinct capsule and crescentic nucleus (LG, ×400) (f) Bone marrow trephine biopsy shows macrophages loaded with yeast forms with a clear space of capsule around each nucleus (H and E, ×400).

inadequate core size or dilution with peripheral blood. This suggests the dependency of both procedures on each other. Among all the cases, AML (72.72% correlation) and ALL (87.23% correlation) showed the highest correlation. This was also observed in other studies.^[3-8] In chronic myeloproliferative neoplasm, both procedures showed equal correlation (100%). This was also seen in other studies.^[3,4,9] However, to classify the stages as acute or chronic, the blast count is important which can be better delineated on aspiration. However, the role of trephine lies in an assessment of the pattern of involvement which determines the prognosis.

In the present study, anemia including the cases of EH (28.19%) was the most common benign hematological disorder among the subset of cases. The highest correlation observed was with IDA (100%). Although micro normoblasts were seen in both, yet iron store assessment required aspiration sections as biopsy yielded false results due to leaching of iron in decalcification. Prussian blue stained slides graded iron stores accurately. Next was MA (83.33%), where both aspiration and biopsy gave an equal correlation. Our findings were concordant with those of Khan *et al.*^[6] and Nanda *et al.*^[10] EH showed a good correlation between aspiration and biopsy with a percentage of 80%. These were subsequently followed up to look for micro normoblasts or macro normoblasts or hypersplenism. A high prevalence of

nutritional anemia can be seen in a tropical country like ours, because of malnutrition and infectious diseases.^[3,11]

Aplastic anemia (AA) was a diagnosis established by biopsy since it had corrected the assessment of the cellularity of marrow. Fifteen out of 22 were correctly established to be aplastic on biopsy. Five out of 22 cases on aspiration (22%) were diagnosed as unclassified due to dilution with peripheral blood. Here, the observed correlation was 68% between aspiration and biopsy. This was in concordance with Mahajan *et al.*^[12] but this showed a disparity with the study done by Gilotra *et al.*^[4] Trephine biopsy imparts further information about quantity and distribution of lymphocytes, plasma cells, megakaryocytes, and blasts which serve as prognostic markers in the follow-up of AA. A positive correlation in cases of immune thrombocytopenic purpura was 68.42%, which was coherent with the study of Gilotra *et al.*^[4] and Khan *et al.*^[6]

Granulomatous inflammation was diagnosed only in one case. The presentation was an HIV infected individual with pyrexia of unknown origin. On BMB, the aspirate smears revealed a reactive marrow with mild increase in plasma cells. This on biopsy showed a well-formed granuloma suspected to be of tuberculous origin. Acid fast bacilli (AFB) showed the presence of beaded bacilli. A reverse transcription polymerase

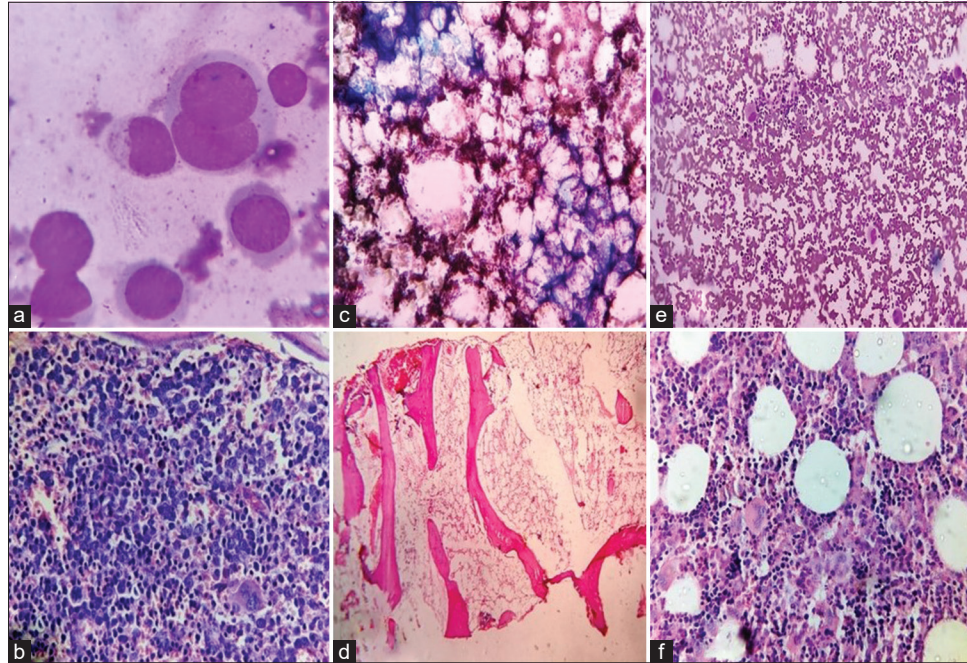


Figure 5: Megaloblastic anemia (a) Bone marrow aspiration smear shows early megaloblasts with open nuclear chromatin and basophilic cytoplasm (LG, $\times 400$) (b) Bone marrow trephine biopsy shows erythroid hyperplasia with predominant megaloblasts having vesicular nuclei (H and E, $\times 400$) Aplastic anemia (c) Bone marrow aspiration smear shows marrow fragments with marked increase in fat (LG, $\times 100$) (d) Bone marrow trephine biopsy shows tiny foci of hematopoiesis and increase in fat space (H and E, $\times 100$) Immune thrombocytopenic purpura (e) Bone marrow aspiration smear shows increased mature and immature megakaryocytes (LG, $\times 100$) (f) Bone marrow trephine biopsy shows erythroid and megakaryocytic hyperplasia (H and E, $\times 400$).

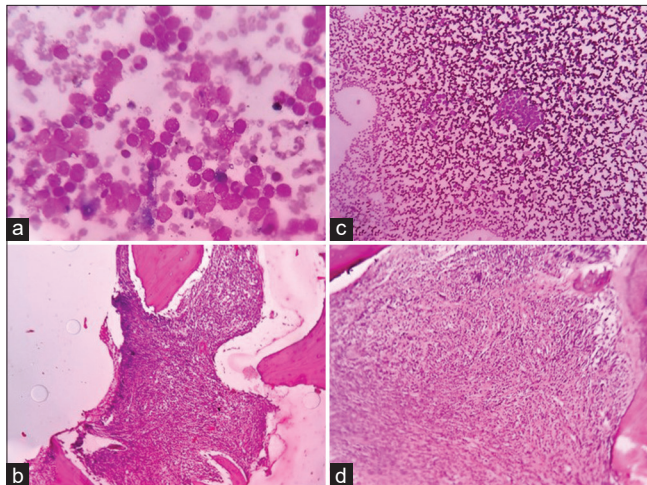


Figure 6: Acute lymphoblastic leukemia (a) Bone marrow aspiration smear shows medium to large sized blasts with variable nuclear size with clumped chromatin and basophilic cytoplasm with vacuolations (LG, $\times 400$) (b) Bone marrow trephine biopsy shows monomorphic blasts cells with coarse nuclear chromatin (H and E, $\times 400$) Neuroblastoma metastatic deposit bone marrow (c) Bone marrow aspiration smear shows a small cluster of tumor cells amongst hemopoietic cells (LG, $\times 400$) (d) Bone marrow trephine biopsy shows total replacement of marrow by metastatic small blue round cells (H and E, $\times 400$).

chain reaction was performed next which confirmed the diagnosis. It is challenging to identify granulomas on aspirate smears because of the focal involvement of the marrow and fibrosis around the granuloma leads to difficult marrow aspiration. Trephine biopsy provides better preservation of morphology and more amount of tissue than aspirate smears; hence, a better means to demonstrate granulomas. Another case was an HIV infected individual with fever and pancytopenia. Here, aspiration procedure established the diagnosis of histoplasmosis. PAS stain was subsequently performed which confirmed the diagnosis.

Cases presenting with rapidly dropping hemoglobin levels had two possibilities. One was pure red cell aplasia (RCA). Second was Parvo viral infection. Here, marrow examination was of paramount importance. Parvo virus infection (parvo immunoglobulin M positive) showed paucity of erythroid precursors with giant proerythroblasts having intranuclear inclusions on BMA. This giant proerythroblast were also picked up on biopsy but the morphology was better appreciated on aspiration. Pure RCA on the other hand showed complete loss of all erythroid lineage. Macrophage activation syndrome (MAS) showed positive correlation of 60% and reactive marrow showed positive correlation of

Table 3: Correlation between BMA and BMB (n=149).

BMBX	BMA																					
	ALL	AML	AL-UN	AA	CML	EH	MA	IDA	MAS	RCA	SD	GR	HS	HIS	MET	MUD	ITP	WD	RM	UN	TOTAL	
ALL	41	0	3	1	0	0	0	0	0	0	0	0	0	0	0	0	0	0	0	0	2	47
AML	0	8	2	0	0	0	0	0	0	0	0	0	0	0	0	0	0	0	0	0	1	11
AL-UN	0	0	0	0	0	0	0	0	0	0	0	0	0	0	0	0	0	0	0	0	0	00
AA	0	0	0	15	0	2	0	0	0	0	0	0	0	0	0	0	0	0	0	0	5	22
CML	0	0	0	0	3	0	0	0	0	0	0	0	0	0	0	0	0	0	0	0	0	3
EH	0	0	0	0	0	4	0	0	0	0	0	0	0	0	0	0	0	0	0	1	0	5
MA	0	0	0	0	0	1	5	0	0	0	0	0	0	0	0	0	0	0	0	0	0	6
IDA	0	0	0	0	0	0	0	9	0	0	0	0	0	0	0	0	0	0	0	0	0	9
MAS	0	0	0	0	0	0	0	0	3	0	0	0	0	0	0	0	0	0	0	1	1	5
RCA	0	0	0	0	0	0	0	0	0	6	0	0	0	0	0	0	0	0	0	0	1	7
SD	0	0	0	0	0	0	0	0	0	0	1	0	0	0	0	0	0	0	0	1	1	3
GR	0	0	0	0	0	0	0	0	0	0	0	0	0	0	0	0	0	0	0	1	0	1
HS	0	0	0	0	0	1	0	0	0	0	0	0	0	0	0	0	0	0	0	0	0	1
HIS	0	0	0	0	0	0	0	0	0	0	0	0	0	1	0	0	0	0	0	0	0	1
MET	0	0	0	1	0	0	0	0	0	0	0	0	0	0	0	0	0	0	0	0	0	1
MUD	0	0	0	0	0	0	0	0	0	0	0	0	0	0	0	0	0	0	0	0	1	1
ITP	0	0	0	0	0	1	0	0	0	0	0	0	0	0	0	0	13	0	4	1	1	19
WD	0	0	0	0	0	0	0	0	0	0	0	0	0	0	0	0	0	1	0	0	0	1
RM	0	0	0	0	0	0	0	0	0	0	0	0	0	0	0	0	0	0	5	1	0	6
UN	0	0	0	0	0	0	0	0	0	0	0	0	0	0	0	0	0	0	0	0	0	0
Total	41	8	5	17	3	9	5	9	3	6	1	0	0	1	0	0	13	1	13	14	14	149

Kappa value=0.6295 (substantial agreement). BMA: Bone marrow aspirate, BMB: Bone marrow biopsies, ALL: Acute lymphoblastic leukemia, AML: Acute myeloblastic leukemia, AA: Aplastic anemia, CML: Chronic myeloid leukemia, EH: Erythroid hyperplasia, MA: Megaloblastic anemia, IDA: Iron deficiency anemia, MAS: Macrophage activation syndrome, RCA: Red cell aplasia, ITP: Immune thrombocytopenic purpura, SD: Storage disorders, GR: Granulomatous inflammation, HS: Hereditary spherocytosis, HIS: Histoplasma capsulatum infection, MET: Metastasis, MUD: Mucinous degeneration, WD: Wilson disease, RM: Reactive marrow, UN: Unclassified, AL-UN: Acute leukemia-unclassified, BMBX: Bone marrow biopsy

Table 4: Comparison of the diagnostic efficacy of BMA and BMB with the previous studies.

Name of the study	Diagnostic efficacy	
	Bone marrow aspiration (%)	Bone marrow biopsy (%)
Aljadayeh <i>et al.</i> ^[3]	76.2	98.8
Gilotra <i>et al.</i> ^[4]	72.4	83.9
Khan <i>et al.</i> ^[6]	73.8	99
Chandra and Chandra ^[7]	77.5	99.2
Present study	77.18	90.6

BMA: Bone marrow aspirate, BMB: Bone marrow biopsies

83.33%. Few other cases which were included in the study were storage disorders (33.33% correlation), hypersplenism and metastasis (neuroblastoma metastasis to bone marrow).

In this study, the majority (77.18%) of the cases showed a significant correlation between the BMA and biopsy findings. This was also observed by Aljadayeh *et al.*^[3] with a positive correlation of 76.2%, Khan *et al.*^[6] with a positive correlation of 73.8% Chandra and Chandra^[7] with a positive correlation of 78%, Gilotra *et al.*^[4] with positive correlation of 87% and Ghodasara and Gonsai^[9] with positive correlation of 73.8%. The diagnostic efficacies of both procedures are compared with the previous studies [Table 4].

There were some limitations in our study. In the given span of time, the number of cases in the subgroups was less, touch imprints were not evaluated in the cases which may have increased the diagnostic accuracy. The nature of the underlying disease and the experience of the physician obtaining the specimen may affect the diagnostic efficacy of both resulting in the highest proportion of non-diagnosed aspirate and hemodiluted biopsies or inadequate samples. The findings of immunohistochemistry, flow cytometry, and cytogenetics were not considered in our study.

CONCLUSION

Bone marrow aspiration and biopsy have the upper hand over each other in their respective area. While cellularity, the pattern of tumor infiltration, and focal diseases are better appreciated on biopsy, aspiration is required for better cytomorphological details appreciation. Both show substantial agreement and hence, these should be performed together and not in isolation to give a complete diagnosis.

Declaration of patient consent

The authors certify that they have obtained all appropriate patient consent.

Financial support and sponsorship

Nil.

Conflicts of interest

There are no conflicts of interest.

REFERENCES

- Riley RS, Williams D, Ross M, Zhao S, Chesney A, Clark BD, *et al.* Bone marrow aspirate and biopsy: A pathologist's perspective II. Interpretation of the bone marrow aspirate and biopsy. *J Clin Lab Anal* 2009;23:259-307.
- Kumar V, Bhatia A, Madaan GB, Marwah S, Nigam AS. Role of bone marrow examination in the evaluation of infections: Clinico-hematological analysis in a Tertiary Care Centre. *Turk Patoloji Derg* 2020;36:17-22.
- Aljadayeh MH, Saidat SD, Kamal N, Obeidat MB, Gamer AS, Sweilmin AM. Comparative evaluation between bone marrow aspirate and biopsy morphologic findings, experience at King Hussein Medical Center. *J Ramanujan Math Soc* 2015;22:18-22.
- Gilotra M, Gupta M, Singh S, Sen R. Comparison of bone marrow aspiration cytology with bone marrow trephine biopsy histopathology: An observational study. *J Lab Physicians* 2017;9:182-9.
- Toi PC, Varghese RG, Rai R. Comparative evaluation of simultaneous bone marrow aspiration and bone marrow biopsy: An institutional experience. *Indian J Hematol Blood Transfus* 2010;26:41-4.
- Khan TA, Khan IA, Mahmood K. Diagnostic role of bone marrow aspiration and trephine biopsy in haematological practice. *J Postgrad Med Inst* 2014;28:217-21.
- Chandra S, Chandra H. Comparison of bone marrow aspirate cytology, touch imprint cytology and trephine biopsy for bone marrow evaluation. *Hematol Rep* 2011;3:e22.
- Surbhi G, Singh UR, Rusia U. Comparative evaluation of bone marrow aspirate with trephine biopsy in hematological disorders and determination of optimum trephine length in lymphoma infiltration. *Mediterr J Hematol Infect Dis* 2014;6:e2014002.
- Ghodasara J, Gonsai RN. Comparative evaluation of simultaneous bone marrow aspiration and bone marrow trephine biopsy-a tertiary care hospital based cross-sectional study. *Int J Sci Res* 2014;10:2058-61.
- Nanda A, Basu S, Marwaha N. Bone marrow trephine biopsy as an adjunct to bone marrow aspiration. *J Assoc Physicians India* 2002;50:893-5.
- Goyal S, Singh UR, Rusia U. Comparative evaluation of bone marrow aspirate with trephine biopsy in hematological disorders and determination of optimum trephine length in lymphoma infiltration. *Mediterr J Hematol Infect Dis* 2014;6:e2014002.
- Mahajan V, Kaushal V, Thakur S, Kaushik R. A comparative study of bone marrow aspiration and bone marrow biopsy in haematological and non-haematological disorders-an institutional experience. *J Indian Acad Clin Med* 2013;14:133-5.

How to cite this article: Das R, Mandal AP, Ghosh M, Sengupta M. Comparison of bone marrow aspiration and biopsy as diagnostic tool in pediatric age group. *J Hematol Allied Sci* 2023;3:11-7.