

Images/Videos in Hematology

Auer rods in a B/myeloid-mixed phenotype acute leukemia

Debadrita Ray¹, Shano Naseem¹¹Department of Hematology, Postgraduate Institute of Medical Education and Research, Chandigarh, India.

*Corresponding author:

Shano Naseem,
Department of Hematology,
Postgraduate Institute of
Medical Education and
Research, Chandigarh, India.

shanonaseem@yahoo.co.in

Received: 12 February 2025

Accepted: 07 March 2025

Epub Ahead of Print: 22 April 2025

Published:

DOI

10.25259/JHAS_9_2025

Quick Response Code:



A 21-year-old female presented with fatigue and fever for 2 weeks. On examination, she had ecchymosis over trunk and limbs. Complete blood count revealed anemia, thrombocytopenia, and leukocytosis. Peripheral blood smear showed 85% blasts, many with Auer rods and myeloperoxidase (MPO) positivity [Figure 1a-c], May-Grunwald-Giemsa × 1000). On flow cytometry immunophenotyping [Figure 1d], blasts were positive for myeloid (CD13, CD33, CD117, and anti-MPO) and B-lineage (CD19, cytoCD79a, and cytoCD22) markers. On molecular genetics analysis, breakpoint cluster region-abelson (*BCR::ABL1*) fusion gene and mixed lineage leukemia (*MLL*) gene rearrangement were negative; however, FMS-like tyrosine kinase 3 internal tandem duplication (*FLT3-ITD*) mutation was positive. A diagnosis of mixed phenotype acute leukemia (MPAL) (B-lymphoid/myeloid) was made.

Auer rods are needle-like structures formed by agglomeration of azurophilic granules. Identification of Auer rods in the blasts is considered as one of morphological features of myeloblasts and is diagnostic for acute myeloid leukemia (AML). The presence of Auer

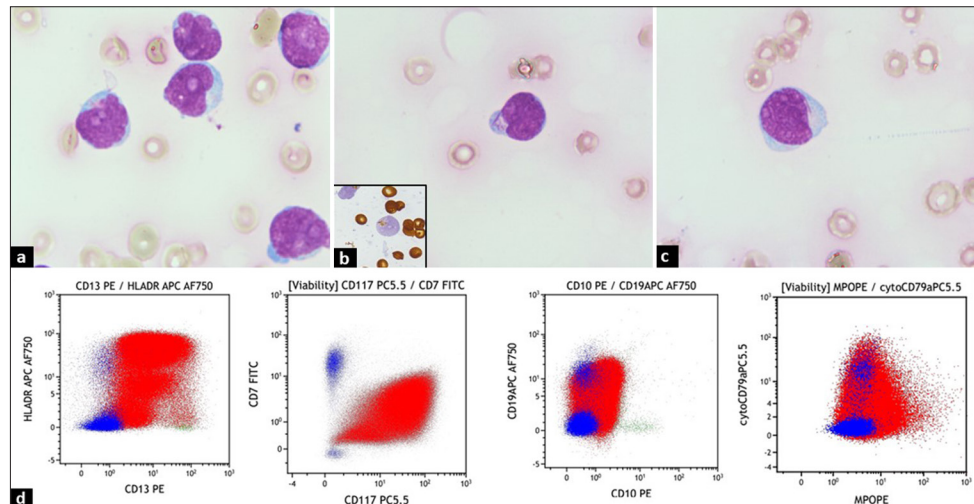


Figure 1: (a-c) Peripheral smear showing blasts with Auer rods and myeloperoxidase (inset in b) positivity (x1000; May Grunwald-Giemsa). (d) Flow cytometry dot plots showing blasts positive for myeloid (CD13, CD33, CD117, anti-MPO) and B-lineage (CD19, cytoCD79a and cytoCD22) markers.

This is an open-access article distributed under the terms of the Creative Commons Attribution-Non Commercial-Share Alike 4.0 License, which allows others to remix, transform, and build upon the work non-commercially, as long as the author is credited and the new creations are licensed under the identical terms.

©2025 Published by Scientific Scholar on behalf of Journal of Hematology and Allied Sciences

rods in MPAL has been very rarely reported. Auer rods are more commonly seen in myeloid/T-lymphoid than myeloid/B-lymphoid subtype of MPAL.

The diagnostic learning in our case is that although the detection of Auer rods does confirm the myeloid lineage and warrant a diagnosis of AML, it is still imperative to perform flow cytometric analysis for exclusion of MPAL.

Ethical approval: The Institutional Review Board approval is not required.

Declaration of patient consent: The authors certify that they have obtained all appropriate patient consent.

Financial support and sponsorship: Nil.

Conflicts of interest: There are no conflicts of interest.

Use of artificial intelligence (AI)-assisted technology for manuscript preparation: The authors confirm that there was no use of artificial intelligence (AI)-assisted technology for assisting in the writing or editing of the manuscript and no images were manipulated using AI.

How to cite this article: Ray D, Naseem S. Auer rods in a B/myeloid-mixed phenotype acute leukemia. J Hematol Allied Sci. doi: 10.25259/JHAS_9_2025