

Images/Videos in Hematology

Isolated cutaneous Langerhans cell histiocytosis in circumcised preputial skin

Sanjiban Patra¹, Priti Trivedi¹

¹Department of OncoPathology, The Gujarat Cancer Research Institute, New Civil Hospital Campus, Ahmedabad, Gujarat, India.

*Corresponding author:

Priti Trivedi,
Department of OncoPathology,
The Gujarat Cancer Research
Institute, New Civil Hospital
Campus, Ahmedabad, Gujarat,
India.

priti.trivedi@gcriindia.org

Received: 22 August 2021

Accepted: 23 August 2021

Epub Ahead of Print: 05 Oct 2021

Published: 07 December 2021

DOI

10.25259/JHAS_21_2021

Quick Response Code:



A 2-year-old child underwent circumcision for phimosis with clinical suspicion of balanitis xerotica obliterans. Histopathological examination of the preputial skin revealed diffuse dermal infiltration by sheets of atypical mononuclear cells [Figure 1a and b] having round to oval convoluted nuclei, nuclear grooves, inconspicuous nucleoli, and abundant eosinophilic cytoplasm [Figure 1c]. Few eosinophils were also evident. On immunohistochemistry, these cells expressed CD1a [Figure 1d] and S-100 diffusely. A diagnosis of cutaneous Langerhans cell histiocytosis (LCH) was rendered. The child was evaluated thoroughly but no other organ or system was involved. No residual lesion was detected by positron emission tomography scan. He had been kept in close follow-up for the past 6 months.

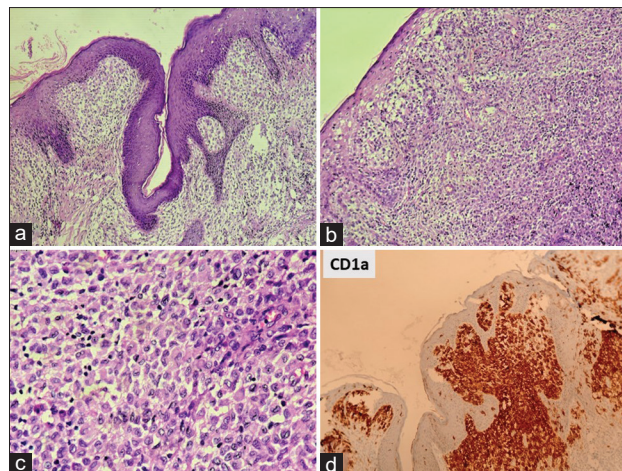


Figure 1: Cutaneous Langerhans cell histiocytosis in preputial skin: (a and b) Showing normal epidermis and diffuse dermal infiltration by sheets of atypical mononuclear cells (H&E, ×100); (c) These atypical cells have round to oval convoluted irregular nuclei, nuclear grooves and moderate to abundant eosinophilic cytoplasm (H&E, ×400) (d) these cells express membranous CD1a diffusely (IHC, ×100) H&E: Hematoxylin & eosin, IHC: Immunohistochemistry.

This is an open-access article distributed under the terms of the Creative Commons Attribution-Non Commercial-Share Alike 4.0 License, which allows others to remix, tweak, and build upon the work non-commercially, as long as the author is credited and the new creations are licensed under the identical terms.

©2021 Published by Scientific Scholar on behalf of Journal of Hematology and Allied Sciences

The differential diagnoses to consider are inflammatory conditions with florid histiocytic reaction and T-cell Non-Hodgkin Lymphoma. However, immunohistochemistry for CD1a, S-100, and T cell markers such as CD2, CD3, and CD5 usually solve the issue.

LCH, is a rare neoplastic condition of myeloid dendritic cells that express CD1a, langerin (CD207), S100, and cytoplasmic Birbeck granules. Isolated cutaneous LCH is extremely rare^[1,2] and usually treated by surgical excision or corticosteroids or rarely multi-agent chemotherapy. Prognosis is good without other system involvement.^[3]

Declaration of patient consent

Patient's consent not required as patients identity is not disclosed or compromised.

Financial support and sponsorship

Nil.

Conflicts of interest

There are no conflicts of interest.

REFERENCES

1. Fronek LF, Grubbs H, Dorton DW, Miller R. Isolated cutaneous langerhans cell histiocytosis presenting in an adult male. *Cureus* 2020;12:e9861.
2. Herbrüggen H, Lakatos K, Gadner H, Minkov M. Isolated cutaneous Langerhans cell histiocytosis in a premature baby: what is the optimal approach? *Pediatr Blood Cancer* 2013;60:163-4.
3. Ng SS, Koh MJ, Tay YK. Cutaneous Langerhans cell histiocytosis: study of Asian children shows good overall prognosis. *Acta Paediatr* 2013;102:e514-8.

How to cite this article: Patra S, Trivedi P. Isolated cutaneous Langerhans cell histiocytosis in circumcised preputial skin. *J Hematol Allied Sci* 2021;1:84-5.