

Original Research

Rare mutations in the beta-globin gene and their clinical phenotypes

Sunistha Bhattacharjee¹, Shouriy Ghosh¹ , Rudra Ray¹, Maitreyee Bhattacharyya¹ 

¹Institute of Haematology and Transfusion Medicine, Medical College and Hospital, Kolkata, West Bengal, India.

***Corresponding author:**

Maitreyee Bhattacharyya,
MBBS, MD, DM,
Director and Head of the
Department, Institute of
Hematology and Transfusion
Medicine, Medical College
Hospital, 88, College Street,
Kolkata, West Bengal, India.

mbhattacharyya@yahoo.co.in

Received: 27 December 2022
Accepted: 06 March 2023
Epub Ahead of Print: 07 June 2023
Published: 11 July 2023

DOI
10.25259/JHAS_37_2022

Quick Response Code:



ABSTRACT

Objectives: Beta-thalassemia is one of the most common inherited genetic disorders and the repertoire of mutations in the beta-globin gene is ever-expanding. Sequencing for beta-globin gene mutations, is done, where phenotype-high-performance liquid chromatography discrepancies exist or where amplification refractory mutation system – polymerase chain reaction (ARMS-PCR) cannot identify common mutations, and often leads to the discovery of rare and novel mutations.

Materials and Methods: This is a retrospective data analysis of 160 patients of beta-thalassemia and other hemoglobinopathies where some patients were found to have unexplained clinical features. Comprehensive genetic diagnosis was done on these patients by ARMS-PCR, gap-polymerase chain reaction, and sequencing.

Results: Out of the total, 124 cases were homozygous/compound heterozygous for beta-thalassemia; 26 cases had heterozygous beta mutations with coexistent alpha-triplications and four patients (with unique clinical features) were found to harbor five rare mutations. The mutations detected were hemoglobin (Hb) Monroe (co-occurring with beta nt-42 mutation), beta-globin mutation –90(C>T), Hb Randwick, and Hb-M-Saskatoon (a variant hemoglobin causing methemoglobinemia and cyanosis). The spectrum of common mutations detected, in our study, was similar to that published in the literature. The unique clinical features of the patients were conclusively explained by the sequencing results.

Conclusion: This study emphasizes the role of sequencing in the genetic diagnosis of beta-thalassemia. As next-generation sequencing increasingly finds use in routine diagnostics, newer clinically significant mutations will continue to be added to the large palette of mutations in beta-thalassemia.

Keywords: Beta-thalassemia, Hemoglobin Monroe, Hemoglobin Randwick, Hemoglobin Saskatoon, Beta –90(C>T), Beta nt-42(C>G)

INTRODUCTION

Beta-thalassemia is one of the most common inherited genetic disorders and has been extensively studied and researched worldwide. The repertoire of mutations in the beta-globin gene is ever expanding and, presently, there are more than 900 mutations in the beta-globin gene, of which 200 mutations are commonly found worldwide.^[1] Mutations may either be clinically silent or lead to the reduced or absent synthesis of the protein, resulting in phenotypes ranging from severe anemia to clinically asymptomatic individuals.^[1] These clinical phenotypes can be predicted by analyzing blood parameters and characterizing hemoglobin (Hb) constituents by high-performance liquid chromatography (HPLC). However, in routine clinical practice, deviations from the expected clinical phenotype necessitate the requirement for molecular analysis and

This is an open-access article distributed under the terms of the Creative Commons Attribution-Non Commercial-Share Alike 4.0 License, which allows others to remix, transform, and build upon the work non-commercially, as long as the author is credited and the new creations are licensed under the identical terms.

©2023 Published by Scientific Scholar on behalf of Journal of Hematology and Allied Sciences

often lead to the discovery of yet new and interesting gene mutations. In India, five common mutations account for 90% of beta-thalassemia and include IVS 1-5G>C (Human genome variation society [HGVS]: HBB: c.92+5G>C), codon 30G>C (HGVS: HBB: c.92G>C), codon 15G>A (HGVS: HBB: c.48G>A), frameshift 41-42(-TTCT) (HGVS: HBB: c.126_129delCTTT), and frameshift 8-9(+G) (HGVS: HBB: c.27dupG).^[2] In the eastern part of the country, Hb E (codon 26G>A; HGVS: HBB: c.79G>A) accounts for a considerable proportion of the thalassemia burden (~5–10% carrier prevalence in the population data).^[3] Our Institute in West Bengal is a nodal center for thalassemia control and sees a large footfall of patients referred from all across the state. Apart from amplification refractory mutation system-polymerase chain reaction (ARMS-PCR) and gap-polymerase chain reaction (gap-PCR), we perform Sanger's sequencing for comprehensive molecular diagnosis of beta-globin gene mutations. Here, we report four patients with rare beta-globin gene mutations and describe their unique clinical phenotypes.

MATERIALS AND METHODS

This retrospective data analysis was conducted at the Institute of Hematology and Transfusion Medicine, Medical College and Hospital, Kolkata. Over 3 years, from January 2017–October 2020, a total of 160 cases underwent comprehensive molecular diagnostics for thalassemia. Cases with clinical phenotype-HPLC discrepancies (e.g., thalassemia trait requiring transfusions), those referred to us for prenatal diagnosis, or those with un-explained HPLC parameters underwent sequencing when conventional molecular diagnostics (ARMS-PCR and gap-PCR) could not elucidate the genotype. Detailed family history, history of consanguineous marriage, transfusion history, and drug history were elicited from the patients. A thorough physical examination of all the patients was done with regard to hepatosplenomegaly, features of iron overload, achievement of growth and development milestones, and endocrinological evaluation. After taking written informed consent, 3–4 mL of blood was taken in ethylenediaminetetraacetic acid ethylenediaminetetraacetic acid-coated vacutainers. A CBC was done using an SYSMEX XP100 automated hematology analyzer (SYSMEX Corporation, Japan) and a peripheral smear was also examined for cellular morphology. Hb-electrophoresis was performed using a BIORAD Variant II beta-thalassemia short program (BIORAD, USA). Initial screening was done by ARMS PCR for a panel of 22 mutations which included the five most common mutations and 17 other less commonly found mutations in India.^[2,4] Gap-PCR was done for alpha-triplication/quadruplications wherever indicated. Those with a non-contributory ARMS-PCR and/or gap-PCR report subsequently underwent DNA sequencing

of the entire beta-globin gene. Technical details followed were those based on the work done by Thein.^[1] Automated DNA isolation was done using Qiacube (QIAGEN, USA). β -globin gene sequencing analysis was done using an ABI-3500 sequence analyzer (ABI Biosystems, USA).

RESULTS

Out of the 160 cases studied, 124 cases (124/160; 77.5%) were found to be homozygous or compound heterozygous for beta-thalassemia by ARMS-PCR. Heterozygous beta mutations with co-existent alpha-triplications/quadruplications were found in 26 cases (26/160; 16.25%). However, the phenotype of ten cases (10/160; 6.25%) were left un-explained by ARMS-PCR and Gap-PCR; these were then subjected to beta-globin gene sequencing. Sequencing analysis revealed five different types of rare mutations in four patients and is described in detail below. The families of these patients were also screened for the mutations. The spectrum of beta-globin gene mutations identified is detailed in [Table 1].

CASE DETAILS

Case 1

An 18-year-old boy presented to the outpatient department (OPD) with microcytic hypochromic anemia and a history of a total of three units of packed cell transfusion at the age of 5 years (Non-transfusion dependent thalassemia [NTDT] phenotype). He was a single child and had no history of thalassemic individuals in the family. On evaluation, he had pallor (Hb = 8.9 g/dL) and jaundice but no organomegaly, skeletal changes, or growth retardation. Serum ferritin was 362 ng/mL. The patient's HPLC was homozygous for beta-thalassemia (HbA0 – 0.5%, HbA2 – 3%, and HbF – 100.3%

Table 1: Spectrum of beta-globin gene mutations detected in the series.

S. No.	Beta mutations (in homozygous or compound heterozygous state)	Allelic frequency among the study population (160 cases) <i>n</i> =No. of alleles (%)
1.	IVS 1-5 (G>C)	181 (56.38)
2.	Codon 26 (G>A)/HbE	62 (19.31)
3.	Codon 30 (G>C)	10 (3.11)
4.	Codon 15 (G>A)	10 (3.11)
5.	FS 41-42 (-TTCT)	8 (2.49)
6.	Codon 6 (A>T)/HbS	3 (0.93)
7.	Asian-Indian inversion deletion (delta-beta)	2 (0.62)
8.	IVS 1-1 (G>T)	2 (0.62)
9.	Rare mutations	5 (1.55)
10.	Undetected mutations	12 (3.73)
11.	Normal allele	26 (8.09)

with pre-integration peaks in the chromatogram) [Figure 1a], while ARMS-PCR showed only a heterozygous CD 15 mutation. Not being able to explain his NTDT phenotype, beta-globin gene sequencing was done. Sequencing revealed, in addition to CD 15 mutation, two rare mutations, namely, Hb Monroe (HGVS name: HBB: c.92G>C, AGG>ACG leading to arginine to threonine amino acid change at nucleotide position 70686, codon 30, exon 1) and beta nt-42 (HGVS name: HBB: c.-92C>G; C>G substitution at nucleotide position 70503 in the promoter region, 42 base pair upstream to exon 1) [Table 2 and Figure 2]. Since both these mutations were of β_0 type and should have led to a transfusion dependent thalassemia (TDT) phenotype, evaluation for alpha deletion was done and as suspected, a single 3.7kb alpha deletion was found, explaining the NTDT phenotype. XMN1 polymorphism (-158, C>T) was also found in the patient and could explain the high HbF value on HPLC. Beta-globin gene sequencing of the parents revealed the mother to be heterozygous for CD 15 and the father, to harbor both mutations Hb Monroe and beta nt-42 (C>G). The patient is doing well on hydroxyurea supplementation and continues to be on follow-up.

Case 2

A 2-year-old boy, beta-trait by Hb HPLC (HbA0 - 78.3%, HbA2 - 4.3%, HbF - 4.8%) [Figure 1b] but requiring

transfusions, came to our OPD for evaluation. He was born to a beta-carrier mother and E-beta, non-transfusion dependent father. ARMS-PCR of the child picked up only an IVS 1-5 (G>C) mutation and could not explain the TDT phenotype. Subsequently, sequencing revealed compound heterozygosity for beta mutations, IVS 1-5 (G>C), and -90 (C>T) (HGVS name HBB: c.-140C>T; a tandem repeat at nucleotide position 70455 in the CACCC box, in the promoter region, upstream to exon 1) [Figure 2]. Alpha triplication was not detected. Parental testing was done and the mother was found to carry the beta -90(C>T) mutation while the father was compound heterozygous for CD 26 and IVS 1-5 (G>C), thus confirming the diagnosis [Table 2].

Case 3

A 5-year-old transfusion dependent boy (first transfusion at 3.5 years; 1 unit/month) was found to be E-beta-thalassemia on Hb HPLC (HbA0 - 3.3%, HbA2 - 60.7%, and HbF - 40.6%) [Figure 1c]. He had pallor, jaundice, and splenomegaly. The father was a beta-thalassemia carrier (HbA2 - 4.8 %, HbF - 0.4%, and HbA0 - 84.6%) with mild jaundice and the mother was found to be a carrier for HbE (HbA2+HbE - 26%, HbF - 0.8%, and HbA0 - 62.8%) and was clinically asymptomatic. As part of a comprehensive genetic diagnosis, ARMS-PCR of the whole family was done to determine the beta-globin gene mutations. The

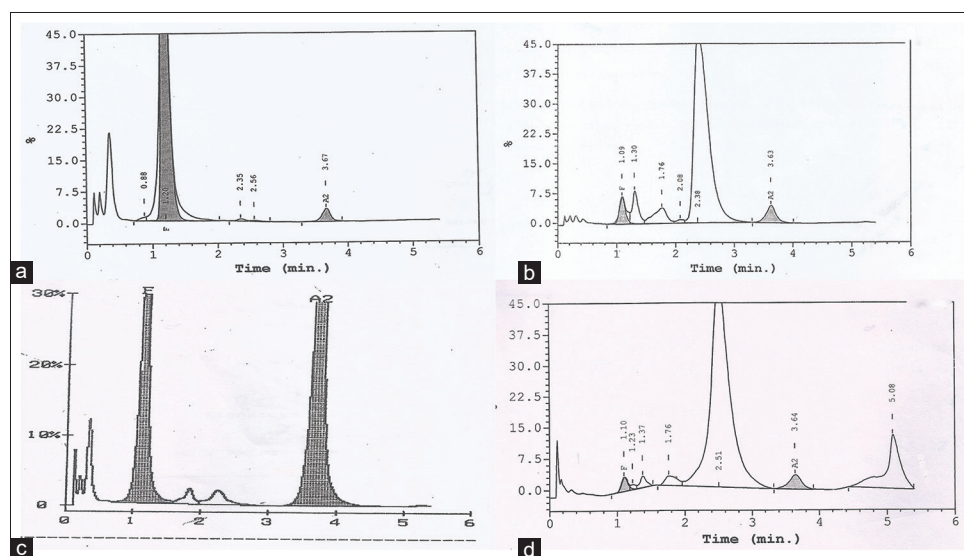


Figure 1: Hemoglobin (Hb) HPLC chromatograms of the four cases described in the text. (a) Case 1: Patient with Hb Monroe, Beta nt-42, and CD15 heterozygous mutations. Chromatogram shows beta-thalassemia major picture with 100.3% HbF, 0.5% HbA0, and 3% HbA2. (b) Case 2: Patient having IVS 1-5(G>C) and beta -90(C>T) mutations. Chromatogram shows beta-thalassemia like picture with 5.6% HbA2, 82.9% HbA0, and 0.9% HbF. (c) Case 3: Patient with Hb Randwick and HbE heterozygous mutations. Chromatogram shows 60.7% HbA2+E, 3.3% HbA0 and 40.6% HbF. (d) Patient with Hb-M-Saskatoon heterozygous mutation. Chromatogram shows a variant peak at C-window (15%) with 75.8% HbA0, 3.4% HbA2 and 1.8% HbF. HPLC: High-performance liquid chromatography.

Table 2: Rare mutations and their phenotypes: Details of the patients, their parents, clinical features, blood parameters, and mutations detected.

S. No.	Family details	Age (years)/sex	Transfusion dependence/ Clinical features	Hb (g/dL)	Red blood cell count (mill/ cumm)	Mean corpuscular volume (fL)	Mean corpuscular hemoglobin (pg)	Red cell distribution width (%)	HbF (%)	HbA0 (%)	HbA2/ HbA2+ HbE*/ Variant peak (%)	Common β -globin gene mutations	Rare β -globin gene mutations	Alpha-globin gene triplications/ deletions
1.	Patient	18/M	No	8.9	3.64	79.1	24.5	35.2	100.3	0.5	3.0	CD 15 heterozygous	Beta nt-42; Hb Monroe heterozygous	3.7kb alpha deletion
	Mother	34/F	No	10.7	5.42	64	19.7	16	2.1	82.4	5.6	CD 15 heterozygous	-	No
	Father	39/M	No	13.3	5.58	73	23.8	16.1	0.9	82.9	5.6	Not found	Beta nt-42; Hb Monroe heterozygous	No
2.	Patient	2/M	Yes	7.1	3.09	68.3	23	27.4	4.8	78.3	4.3	IVS 1-5 heterozygous	Beta-90 (C>T) heterozygous	No
	Mother	26/F	No	12.3	5.71	69.2	21.5	14.9	1.5	83.5	5.7	Not found	Beta-90(C>T) heterozygous	No
	Father	32/M	No; Mild jaundice+	8.4	5.4	54	16.4	22.1	12	9.9	67.2*	CD 26 heterozygous	-	No
3.	Patient	7/M	Yes	5	2.77	60	18	33.4	40.6	3.3	60.7*	IVS 1-5(G>C) CD 26 heterozygous	Hb Randwick heterozygous	No
	Mother	26/F	No	12.9	5.04	78.8	25.6	14.2	0.8	62.8	26*	CD 26 heterozygous	-	No
	Father	29/M	No	11.9	6.39	61.2	18.6	17.2	0.4	84.6	4.8	Not found	Hb Randwick heterozygous	No
4.	Patient	2/F	No; Cyanosis+	9.2	3.42	91.5	27.8	18	1.8	75.8	3.4/Variant peak ^s	None	Hb M Saskatoon heterozygous	No
	Mother	26/F	No	14.6	4.46	104.5	33	15	0.2	96.5	3.1	None	-	No
	Father	30/M	No	9.0	4.06	94.8	22.2	17.8	0.6	87.8	2.7	None	-	No

^sHbC window: Variant peak – 15% at retention time of 5.08 min. Hb: Hemoglobin, *, HbE

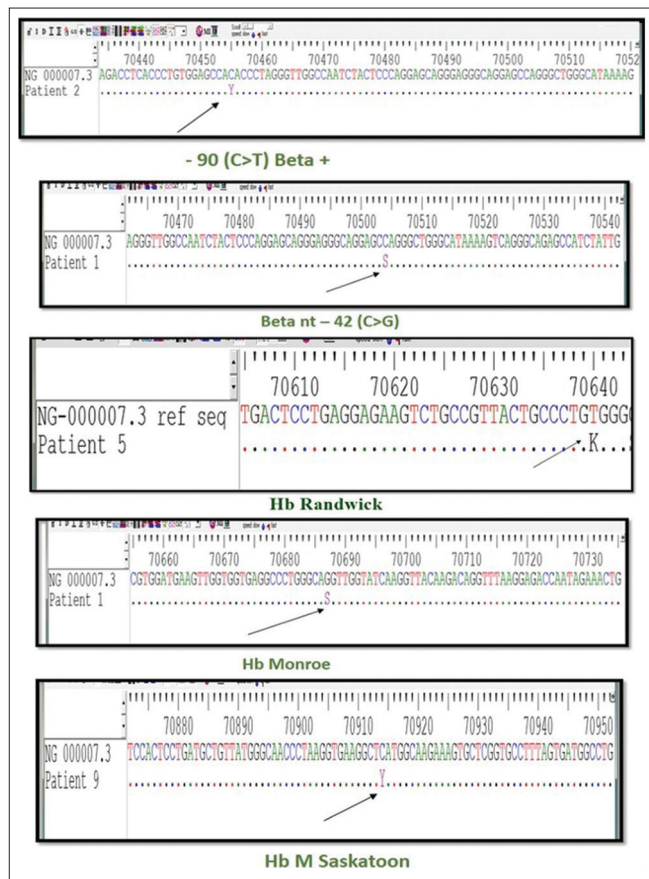


Figure 2: Snap-Gen software readout of the sequences showing beta mutation –90 (C>T), Hb Monroe, Hb Randwick, Hb-M-Saskatoon, and beta nt-42 (C>G) mutations. Hb: Hemoglobin.

mother was found to be heterozygous for CD 26 (G>A)/HbE mutation, while common beta-globin gene mutations were not found in the father. The child, on ARMS-PCR, was heterozygous for CD 26 (G>A). To evaluate the nature of the second beta-globin allele mutation, sequencing was done which revealed Hb Randwick (HGVS name: HBB: c.46T>G; nucleotide change from TGG>GGG, leading to tryptophan to glycine amino acid change at position 70640, codon 15, exon 1) [Figure 2]. The same mutation (Hb Randwick) was identified in the father by sequencing, thus completing the evaluation of the child [Table 2].

Case 4

A 2-year-old female child was referred to us for evaluation of persistent central cyanosis since 8 months of age. The child did not have history of cardiovascular or respiratory illnesses or growth and developmental anomalies. Physical examination, arterial blood gas analysis, echocardiography, and chest imaging were within normal limits, except for low SpO₂ on pulse oximetry (68%) which did not improve with oxygen supplementation. With a working diagnosis of

methemoglobinemia causing pseudocyanosis, possibly due to a variant Hb, her blood parameters were tested which showed Hb = 9.5 g/dL, MCV of 91.5 fl, MCH of 27.8 pg and a normal reticulocyte count. HPLC analysis showed a normal Hb A0 (75.8%), Hb A2 (3.4%), Hb F values (1.8%), and a peak in the C-window – 15% at a retention time of 5.08 min [Figure 1d]. ARMS-PCR was non-contributory to the common beta mutations. DNA sequencing revealed that the child was carrying a rare mutation in the heterozygous state at Codon 63 (CAT>TAT) in Exon 2 causing a change in amino acid sequence from His > Tyr. The mutation was cross-referenced with the globin gene server (<http://globin.cse.psu.edu/cgi-bin/hbvar/coorSeqCheck>) and was detected as Hb-M-Saskatoon mutation (HGVS name HBB: c.190C>T) [Table 2 and Figure 2]. There were no alpha deletions or triplications in the child. The parents were also subjected to beta-globin gene sequencing, but the mutation was not found in either parent thus establishing the *de novo* nature of the mutation in the child. The parents were counseled regarding the benign nature of the condition and advised follow-up.

DISCUSSION

As sequencing technologies advance and become more accessible and affordable, the repertoire of mutations in thalassemia will continue to expand. In this study, we used Sanger's sequencing, in addition to ARMS and Gap-PCR, as part of comprehensive genetic diagnosis and could evaluate 154 out of the 160 cases of thalassemia with unexplained clinical features. Six cases (6/160, 3.75%) were left undiagnosed even after sequencing analysis. The spectrum of beta-globin gene mutations found in this study closely match with that reported in the literature from the same geographical region.^[2,5] Alpha-triplication occurring together with beta-thalassemia trait, leading to a TDT phenotype was seen in 26 cases (26/160, 16.25%), which again closely matches with the prevalence in India.^[6,7] We found four cases out of 160 (2.5%) to have rare mutations.

The adolescent in the first case was unique in having a conflicting pattern of homozygous beta-thalassemia on HPLC, but with an NTDT phenotype. Sequencing revealed three mutations, namely, CD 15, Hb Monroe (HBB: c. 92G>C), and beta nt-42 (HBB: –92C>G), along with a single 3.7 kb alpha deletion. Hb Monroe was initially reported in an African-American girl who was transfusion dependent.^[8] This mutation in homozygous state leads to a TDT phenotype and in the heterozygous state, has been reported to interfere with the normal/wild-type allele as it reduces splicing efficiency.^[8-11] Another unique feature of Hb Monroe is co-occurrence with the promoter mutation –92C>G and co-localization on the same allele (downstream and upstream, respectively) of the beta-globin gene. This pair of mutations have been reported in various parts of the world, including

India.^[9,12-14] The significance of this co-occurrence is yet unknown. The mutation at the promoter region, beta nt-42 (HBB: -92C>G), has been postulated to be the binding site for transcription factor Egr1, a target for hydroxyurea to increase HbF production.^[12] In our patient, the severity of these mutations was offset by the presence of alpha deletion and XMN1 polymorphism. Both XMN1 polymorphism and the promoter region mutation made it worthwhile to prescribe hydroxyurea to the patient.^[12]

The child in case 2 had a transfusion-dependent phenotype with compound heterozygosity for IVS 1-5(G>C) and -90(C>T) mutations. The former leads to a beta⁰ state, while the latter is a promoter region mutation (T for C substitution at -90 position upstream in the CACCC box), leading to a reduction of beta-globin protein synthesis causing a beta⁺ state.^[15,16] In combination, this child had a beta⁰/beta⁺ phenotype, and could explain the thalassemia major phenotype. This mutation and others (-87 [C>G] and -88 [C>T]) in the promoter region are rare and mostly lead to a beta⁺/beta⁺⁺ phenotype. Only a few cases of -90(C>T) have been reported previously in India (in West Bengal, Assam, Orissa) and abroad (Portugal).^[17,18] The unique distribution of this mutation may be related to India's colonial past. In our case, the mother was the carrier of the rare mutation and had a similar hemogram (Hb = 12.3 g%, MCV = 69.2 fl, MCH = 21.5 pg, and RDW = 14.9) and HPLC (HbA⁰ = 83.3%, HbF = 1.5%, HbA² = 5.7%) profiles as previously reported in the literature.^[18]

Hb Randwick was detected in case 3 and is found to have a North Italian ethnic background.^[19] This mutation is reported to have normal clinical, HPLC, and hemogram parameters with mild reticulocytosis and may occasionally present with HbH such as inclusions, fragmented, and target cells in peripheral smear.^[19] The mutation is not associated with splenomegaly or jaundice. In our case however, the father was found to carry the mutation and also had a high HbA² value (4.8%) which is in contrast to that reported in the literature (normal HbA² values). Another possibility is that the father also harbored another beta-globin mutation which led to the high HbA² value but could not be detected on genetic analysis. In our patient, this mutation was found in a compound heterozygous state with HbE and the child was transfusion dependent. It is therefore intriguing to see this change in behavior of the mutation when present along with HbE. A corollary may be drawn from the HbE-beta compound heterozygous state which manifests as an NTDT or TDT phenotype, whereas, in isolation, HbE homo/heterozygous state is clinically benign. To the best of our knowledge, this is the first clinically symptomatic case of Hb Randwick reported in the literature.

The fourth case of Hb-M-Saskatoon was detected in a patient with cyanosis. This slightly unstable variant Hb was

first described in 1948 as an autosomal dominant inherited disorder and is associated with decreased oxygen affinity and mild anemia.^[20] This mutation has been previously reported in two families in India.^[21] In Hb HPLC, the presentation can be varied, possibly due to post-translational modification of the Hb moiety. It either elutes solely at the A² window (recently described sporadic case of Hb-M-Saskatoon from Spain had HbA²+variant of 14%), may coelute at A² and C windows or may even have unknown peaks near the C-window with retention times ranging from 4.3 to 4.8 min.^[21,22] In our patient, the abnormal Hb eluted at the C-window (15%), while A² levels were normal. As it is an unstable Hb, cases may manifest with mild hemolysis and consequent reticulocytosis but rarely requires transfusion support.^[22] It is characterized by pseudocyanosis (due to plasma methemoglobin >5 g/dL) which becomes clinically apparent 6-7 months after birth as HbA production reaches its peak. Our patient had similar clinical features when compared to the Spanish report: both were sporadic and presented with anemia and cyanosis. However, the Spanish patient had mild anemia and reticulocytosis without any evidence of hemolysis, while ours did not.^[22] In terms of prognosis, the homozygous state of Hb-M-Saskatoon has not been described in the literature and its behavior is not known, but the heterozygous state is clinically benign, has excellent outcomes, and rarely needs therapy.

CONCLUSION

Rare mutations in thalassemia have myriad presentations. It is even more intriguing to find identical mutations in seemingly disconnected parts of the world, in completely different ethnic groups. Whether these mutations arose simultaneously in different parts of the world or travelled along with the migration of humans from one continent to another still remains unanswered. The study of human genetics in relation to anthropology and history is key to the answer to these questions. In the present day, next-generation sequencing will be an indispensable tool in the hands of the diagnostician to unravel such enigmatic cases. Therefore, we expect yet new and clinically significant mutations to be added to the already vast palette of thalassemia genetics in the years to come.

Author contributions

Sunistha Bhattacharjee, MSc: Concept, molecular work, literature review. Shouriy Ghosh, MD: Concept, clinical data curation, manuscript drafting, editing, and literature review. Both Sunistha Bhattacharjee and Shouriy Ghosh contributed equally to this work. Rudra Ray, Ph.D.: Concept, molecular work, manuscript editing. Maitreyee Bhattacharyya, DM: Concept, manuscript editing, overall supervision.

Ethics approval

Retrospective data analysis. Ethical approval exempted.

Availability of data and material

Available for publication/review.

Statement of prior presentation

Parts of this paper have been presented previously at the annual conference of the Bengal Society of Hematology, 2019 (BeSHCON 2019).

Declaration of patient consent

The authors certify that they have obtained all appropriate patient consent.

Financial support and sponsorship

Nil.

Conflicts of interest

There are no conflicts of interest.

REFERENCES

1. Thein SL. The molecular basis of β -thalassemia. *Cold Spring Harb Perspect Med* 2013;3:a011700.
2. Ghosh K, Colah R, Manglani M, Choudhry VP, Verma I, Madan N, *et al.* Guidelines for screening, diagnosis and management of Hemoglobinopathies. *Indian J Hum Genet* 2014;20:101-19.
3. Dolai TK, Dutta S, Bhattacharyya M, Ghosh MK. Prevalence of hemoglobinopathies in rural Bengal, India. *Hemoglobin* 2012;36:57-63.
4. Colah R, Italia K, Gorakshakar A. Burden of thalassemia in India: The road map for control. *Pediatr Hematol Oncol J* 2017;2:79-84.
5. Sinha S, Black ML, Agarwal S, Colah R, Das R, Ryan K, *et al.* Profiling β -thalassaemia mutations in India at state and regional levels: Implications for genetic education, screening and counselling programmes. *Hugo J* 2009;3:51-62.
6. Panigrahi I, Mahapatra M, Kumar R, Kumar G, Ved PC, Saxena R. Jaundice and alpha gene triplication in beta-thalassemia: Association or causation? *Hematology* 2006;11:109-12.
7. Nadkarni A, Phanasaonkar S, Colah R, Mohanty D, Ghosh K. Prevalence and molecular characterization of α -thalassaemia syndromes among Indians. *Genet Test* 2008;12:177-80.
8. Gonzalez-Redondo JM, Stoming TA, Kutlar F, Kutlar A, McKie VC, McKie KM, *et al.* Severe Hb S-beta zero-thalassaemia with a T----C substitution in the donor splice site of the first intron of the beta-globin gene. *Br J Haematol* 1989;71:113-7.
9. Bakhle A, Dsa L, Bhanushali A, Nair P, Silveira M, Das B. Homozygous hemoglobin Monroe (codon 30 G>C) in a child of Goan (Indian) origin: A case report and family study. *J Appl Hematol* 2018;9:151.
10. Hamid M, Shariati G, Saberi A, Kaikhaei B, Galehdari H, Mohammadi-Anaei M. Identification of IVS-I(-1)(G>C) or Hb Monroe as a report on the beta- globin gene with a beta- thalassemia minor phenotype in south of Iran. *Arch Iran Med* 2013;16:563-4.
11. Agarwal N, Kutlar F, Mojica-Henshaw MP, Ou CN, Gaikwad A, Reading NS, *et al.* Missense mutation of the last nucleotide of exon 1(G->C) of β globin gene not only leads to undetectable mutant peptide and transcript but also interferes with the expression of wild allele. *Haematologica* 2007;92:1715-6.
12. Moosa MM, Ayub MI, Bashar AE, Sarwardi G, Khan W, Khan H, *et al.* Combination of two rare mutations causes β -thalassaemia in a Bangladeshi patient. *Genet Mol Biol* 2011;34:406-9.
13. Fedorov AN, Nasyrov FY, Smirnova EA, Bocharova TN, Limborska SA. IVS-1-1 (g>c) in combination with-42(c>g) in the promoter region of the β globin gene in patients from Tajikistan. *Hemoglobin* 1993;17:275-8.
14. Nagar R, Sinha S, Raman R. Genotype-phenotype correlation and report of novel mutations in β -globin gene in thalassemia patients. *Blood Cells Mol Dis* 2015;55:10-4.
15. Treisman R, Orkin SH, Maniatis T. Specific transcription and RNA splicing defects in five cloned β -thalassaemia genes. *Nature* 1983;302:591-6.
16. Kazazian HH Jr., Orkin SH, Antonarakis SE, Sexton JP, Boehm CD, Goff SC, *et al.* Molecular characterization of seven beta-thalassemia mutations in Asian Indians. *EMBO J* 1984;3:593-6.
17. Edison ES, Shaji RV, Devi SG, Moses A, Viswabandhya A, Mathews V, *et al.* Analysis of β globin mutations in the Indian population: Presence of rare and novel mutations and region-wise heterogeneity. *Clin Genet* 2008;73:331-7.
18. Faustino P, Osório-Almeida L, Barbot J, Espírito-Santo D, Gonçalves J, Romão L, *et al.* Novel promoter and splice junction defects add to the genetic, clinical or geographic heterogeneity of β -thalassaemia in the Portuguese population. *Hum Genet* 1992;89:573-6.
19. Gilbert AT, Fleming PJ, Sumner DR, Hughes WG, Ip F, Kwan YL, *et al.* Hemoglobin Randwick or beta 15(A12) Trp>Gly: A new unstable beta-chain hemoglobin variant. *Hemoglobin* 1988;12:149-61.
20. Horlein H, Weber G. About chronic familial methemoglobinemia and a new modification of methemoglobin. *Dtsch Med Wochenschr* 1948;73:476-8.
21. Gupta O, Chhabra S, Kaur J, Das R, Bansal D, Malhotra P, *et al.* Unusual C-and A2-window peaks (hemoglobin M-saskatoon) in three North Indian patients. *Indian J Hematol Blood Transfus* 2019;35:196-8.
22. García-Morin M, Manrique-Martin G, Ropero P, Bardón-Cancho E, García-Rovés RA, Beléndez C, *et al.* Hb M-saskatoon: An unusual cause of cyanosis in a Spanish child. *Pediatr Hematol Oncol J* 2019;4:23-6.

How to cite this article: Bhattacharjee S, Ghosh S, Ray R, Bhattacharyya M. Rare mutations in the beta-globin gene and their clinical phenotypes. *J Hematol Allied Sci* 2023;3:18-24.